

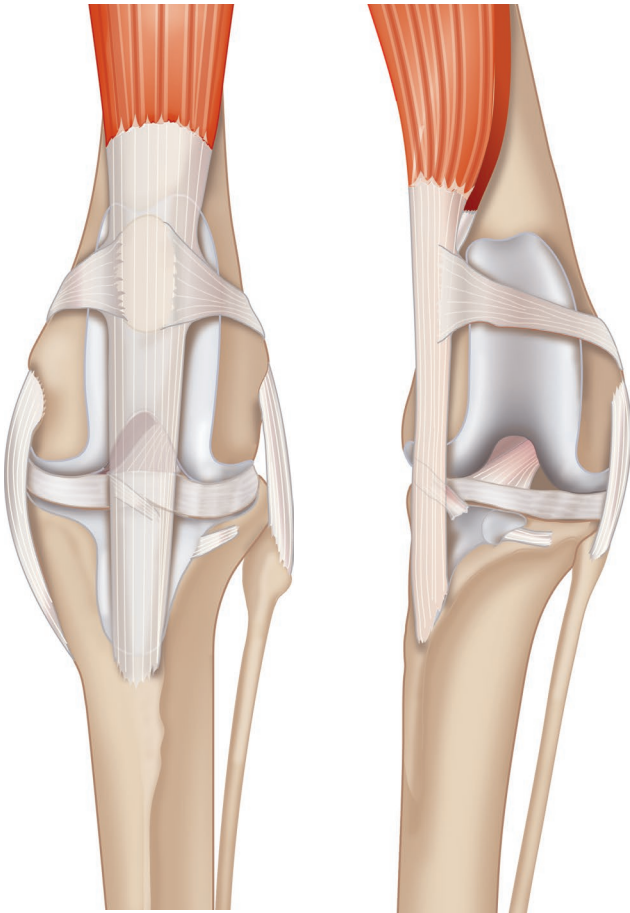


# **Surgery Guide**

## **Patellar Luxation**



# Surgery Guide: Patellar Luxation



Patellar luxation is the condition where the patella luxates out of the femoral trochlear sulcus instead of tracking up and down within it. Most commonly the patella luxates medially but lateral luxation also occurs. It can occur in any size or breed of dog but is more common in small breed dogs.

Cats have a broad and flat patella and the femoral trochlear sulcus is shallow; therefore the normal cat patella is much more mobile medial to lateral and relatively unstable compared to dogs.

Patellar subluxation is common in cats but clinically significant patellar luxation is uncommon.

## Contents

- Diagnosis and Grading of Patellar Luxation
- Causes of Patella Luxation
- Surgical Solutions
- Surgical Technique for Medial Patellar Luxation
  - Initial Approach and Assessment
  - Block Recession Sulcoplasty
  - Wedge Recession Sulcoplasty
  - Tibial Tuberosity Transposition
  - Other Potential Surgical Techniques
- Featured Products



## Diagnosis and Grading of Patellar Luxation

Patellar luxation is usually a diagnosis made from the patient history and signalment, and by stifle manipulation and palpation, rather than from radiographs. This is because the luxating patella is mobile and can change position which can be easily palpated but not necessarily appreciated on a radiograph. Patellar luxation is graded depending on its severity and there are many ways of doing this. The most commonly used grading system is the Putnam/Singleton system which can be described as:

**Grade 1:** The patella tracks normally but luxates with digital pressure or manipulation of the tibia. Once manipulation is discontinued, the patella tracks normally in the trochlear groove. This causes minimal clinical problem with infrequent or no clinical signs. Surgical correction is not usually indicated nor of direct benefit to the patient.

**Grade 2:** The patella intermittently and spontaneously luxates and resolves. This may be mild and infrequent to severe and frequent, and anywhere in-between. Luxation normally happens as the stifle is flexed, and resolves when the stifle is extended. The typical history is of a dog with intermittent skipping hindlimb lameness. Surgical correction is usually of benefit to the patient, particularly the more frequently the patellar luxation occurs.

**Grade 3:** The patella is always luxated but can be returned to the normal position in the trochlear sulcus by digital manipulation. Once such manipulation stops, patellar luxation recurs. This causes an abnormality of stifle function i.e. inability to extend the stifle and associated hindlimb lameness. Surgical correction is beneficial to the patient as it restores normal stifle function, including the quadriceps' ability to extend the stifle.

**Grade 4:** The patella is permanently luxated and cannot be reduced to a normal position despite manipulation. This causes permanently abnormal stifle function with lameness and inability to extend the stifle, and can result in debilitating lameness with a crouched pelvic limb stance and gait. Surgical correction is of benefit. In puppies and young dogs with severe grade 4 developmental patellar luxation, surgery should be considered as soon as possible to prevent the progression of skeletal deformities that may otherwise develop. Surgical correction of grade 4 patellar luxation is challenging, with high rates of post-operative complications including patellar relaxation.

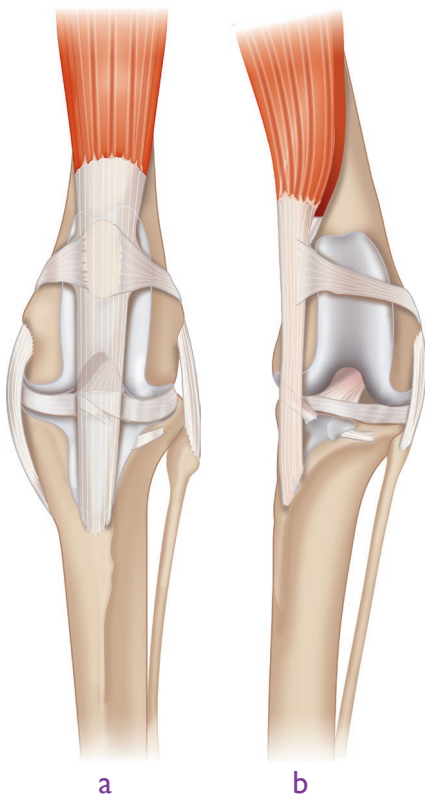
*N.B. Throughout this text for the purpose of clarity, patellar luxation and its treatment will refer to medial patellar luxation (MPL). For cases of lateral patellar luxation (LPL), the terminology and text is interchangeable but references to position should be switched i.e. medial to lateral and vice versa. Traditionally, the surgical approach for MPL has been lateral, and for LPL has been medial. However, as the technique has evolved, many surgeons will now make their approach from the same side as the luxation, therefore incising through the tissues that may be abnormally tight on the side to which the patella luxates; e.g. for cases of medial patellar luxation the medial release and the medial surgical approach are one and the same.*

*There is also an argument for a medial incision to minimise the scar on the more visible lateral aspect of the limb, particularly in short-haired breeds where the surgical scar may remain visible. This guide may therefore state 'medial or lateral' at certain points during the surgical steps, to reflect that there is no 'absolute' correct approach.*



## Causes of Patellar Luxation

Patellar luxation is usually caused by a combination of different factors. For successful correction, the surgeon must make an individual assessment of each patient, identify each factor present, and correct each individually. The common problems are outlined below:



**a.** conformation of pelvic limb of normal dog.

**b.** conformation of pelvic limb of dog with medial bowing (varus) of the femur, internal rotation of the tibia and medial tibial tuberosity malpositioning i.e. malalignment of the quadriceps mechanism relative to the femoral trochlear sulcus, and medial patellar luxation.

### Malalignment of the Quadriceps Mechanism and Trochlear Sulcus

The stifle extensor mechanism comprises the quadriceps muscle with the origin of the three vastus muscles on the proximal femur and rectus femoris on the pelvis just cranial to the acetabulum, the patella, patellar tendon/ligament and tibial tuberosity. The relative position of these, in particular the patella and the trochlear sulcus is important. For normal patellar tracking, the line-of-pull of the quadriceps mechanism and the patella should lie directly over the femoral trochlear sulcus.

Factors that affect quadriceps alignment are:

- Bowing of the distal femur. This changes the position and alignment of the femoral trochlear sulcus relative to the quadriceps mechanism. Femoral bowing can be assessed from physical assessment, radiographs and CT images, but interpretation can be challenging.
- Tibial malformation i.e. a rotational (torsional) deformity of the tibial tuberosity can cause malalignment of the quadriceps mechanism due to abnormal positioning of the tibial tuberosity relative to the femoral trochlear sulcus.
- Bowing of the proximal tibia; often the proximal tibia is bowed in the opposite direction to the distal femur.
- Hip conformation and pathology; for example cranio-dorsal hip luxation causes functional foreshortening of the femur with external rotation; this in turn causes quadriceps/ femoral trochlear sulcus malalignment and patellar luxation can occur.

### Shallow Femoral Trochlear Sulcus

Too shallow a sulcus or insufficiently high medial or lateral trochlear ridges can result in inadequate constraint of the patella and subsequent luxation. Assessment of sulcus depth and trochlear ridge height is subjective; there is no guide that readily differentiates normal from abnormal.

### Excessively Tight Medial Soft Tissues

If the soft tissues medial to the patella (i.e. the retinaculum and joint capsule) are too tight, they will constrain its movement by permanently 'pulling' it medially. It is likely that these tissues become tight as a consequence of chronic patellar luxation, rather than being a cause of it.

## Slack Lateral Soft Tissues

If the lateral soft tissues (i.e. retinaculum, joint capsule and femero-patellar ligament) are too loose, then the patella is not 'pulled' or constrained laterally i.e. patellar luxation can occur. These tissues are loose in the opposite direction to the patellar luxation, and most likely develop as a result of patellar luxation rather than causing it.

## Co-Existing Rupture of the Cranial Cruciate Ligament

Patellar luxation may occur in association with cranial cruciate ligament rupture. When the cranial cruciate ligament ruptures, cranial and internal rotational stability of the tibia relative to the femur is lost; this causes malpositioning of the tibial tuberosity relative to the femoral sulcus, and quadriceps malalignment. TPLO, TTA, TTAR or lateral fabella suture may be performed in cases with concurrent cranial cruciate ligament disease.

## Surgical Solutions

The four commonly performed surgical options to correct patellar luxation include:

**Femoral Trochlear Sulcoplasty** Deepening of the trochlear sulcus to constrain the patella and prevent luxation. This is done if the trochlear sulcus is assessed as too shallow.

**Tibial Tuberosity Transposition** Realignment of the quadriceps mechanism by means of an osteotomy and repositioning the tibial tuberosity more laterally. This is done if malalignment of the quadriceps mechanism and the femoral trochlear sulcus are present.

**Medial Release** Transection of the medial soft tissues (joint capsule and/ or retinaculum) if they are excessively tight. This is done if medial soft tissue tension prevents the patella from tracking in the trochlear sulcus, usually only necessary in grade 3 or 4 luxations.

**Lateral Imbrication** Tightening of the soft tissues (joint capsule and retinaculum) to prevent patellar luxation. This is done if the soft tissues are too loose, but it should not be relied on to correct patellar luxation because future tissue loosening will likely develop if quadriceps alignment or inadequate sulcus depth persist. Medial release and lateral imbrication are performed in addition to other procedures - they are not sufficient in isolation to correct a luxating patella.

Other surgical procedures may be used to correct patellar luxation, but these are more demanding procedures.

- Corrective osteotomies of the distal femur and/ or proximal tibia may be performed if there is significant femoral/ tibia malalignment. Femoral corrective osteotomy is indicated when femoral varus measures more than 12 - 15 degrees.
- Partial parasagittal patellectomy may be performed in cats if patellar luxation cannot be constrained using traditional means.
- If significant hip pathology is present, such as hip subluxation, this may need to be addressed to successfully correct patellar tracking. However, these are demanding surgeries, and best undertaken by experienced surgeons.

# Surgical Technique for (Medial) Patellar Luxation

## Initial Approach and Assessment

1.

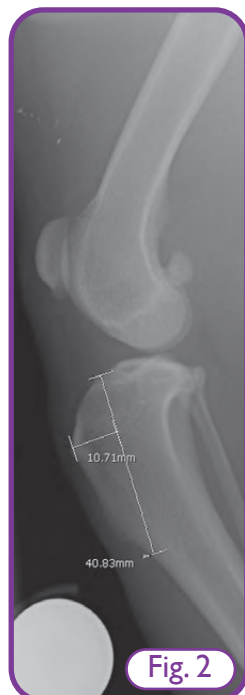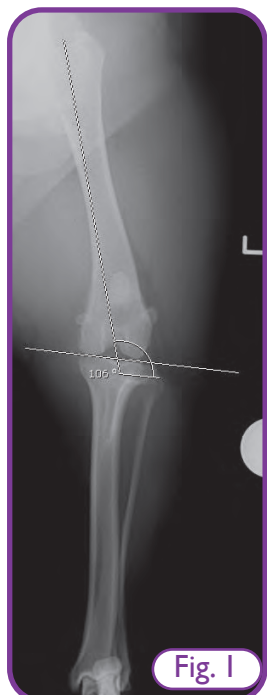Pre-operative assessment includes a full clinical examination of the patient including gait assessment and orthopaedic examination. Patellar stability and pelvic limb alignment should be assessed.

2.

Take orthogonal radiographs of the stifle. Include a straight caudo-cranial view of the femur to allow femoral varus to be assessed (Fig. 1).

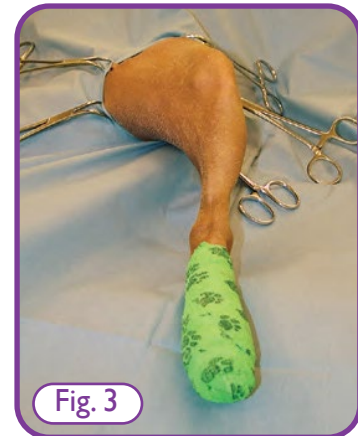Very careful and specific positioning of the femur is required to achieve a true CdCr view of the femur that will give a correct measurement of femoral varus. Femoral alignment can also be measured by CT scan.

A femur with varus angle less than 12 degrees does not need a femoral corrective osteotomy. A femur with varus angle of 15 or more degrees arguably should have corrective osteotomy. The radiographs allow other differential diagnoses to be excluded, possibly the diagnosis to be confirmed, and preoperative measurements made to plan the correct position of the osteotomy for tibial tuberosity transposition (Fig 2).



3.

Position the patient in dorsal recumbency and prepare a full aseptic surgical preparation of the limb with the entire distal limb draped and the foot in a sterile impervious dressing (Fig. 3). This allows full access and manipulation of the limb during surgery.

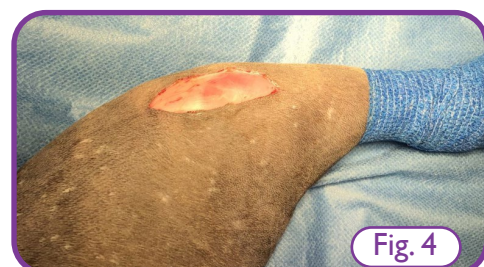

4.

Before starting the surgery, check patella position and anatomic landmarks that will guide the surgery i.e. patella, patellar ligament and tibial tuberosity. Visualise the patellar ligament/tendon and assess whether it is laterally, neutrally or medially positioned from patella to tibial tuberosity. Do this with the tibia internally rotated, in neutral, and externally rotated. This will give an indication of whether a tibial tuberosity transposition is necessary, and if so by how much.

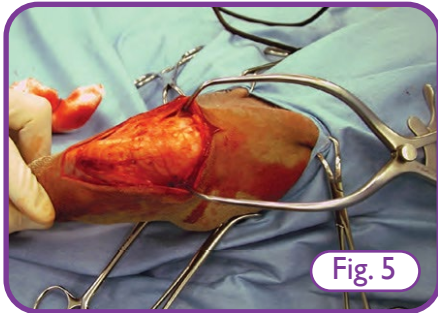
5.

Make a medial or lateral para-patellar skin incision over the stifle about 1cm lateral to the patella, extending from proximal to the patella to the tibial tuberosity (Fig. 4).



6.

Dissect the subcutaneous fascia until the patellar ligament and tibial tuberosity are clearly seen (Fig. 5).

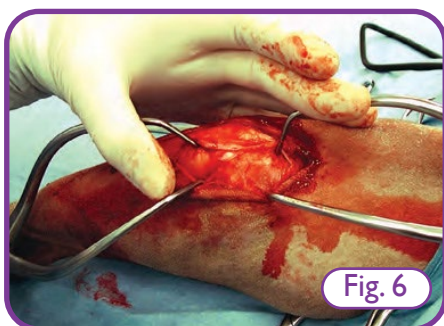


7.

Repeat assessment of the alignment of the quadriceps mechanism. Stand at the toe of the dog and visualise the course and position of the quadriceps mechanism (patellar ligament). Review this whilst flexing the stifle and internally rotating the tibia. Note whether the quadriceps mechanism is aligned or malaligned i.e. does the patellar ligament deviate medially, laterally or is it neutral?

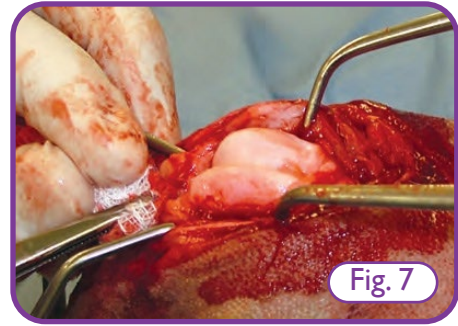
8.

Sharply incise the medial or lateral retinaculum approx. 1cm lateral to the patella. Dissect free from the underlying joint capsule. This incision extends proximal to the patella. The joint capsule is exposed underneath (Fig. 6).



9.

Sharply incise the joint capsule. This incision extends proximal to the patella, extending slightly into distal vastus medialis or lateralis. Use suction to aspirate synovial fluid. Luxate the patella, flex the stifle and use Gelpi retractors to maintain position (Fig. 7).

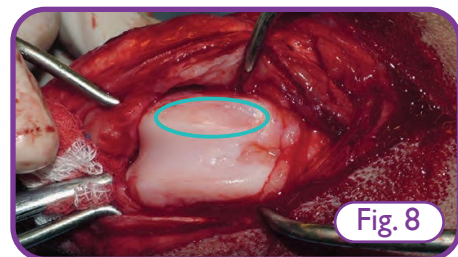


10.

Inspect and confirm that the cranial cruciate ligament is normal.

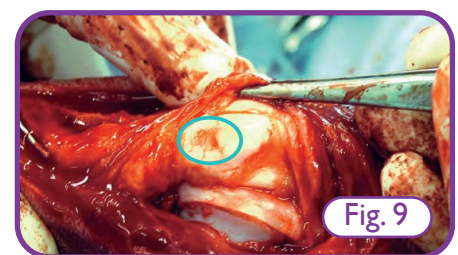
11.

Assess the depth of the trochlear groove (subjective), and inspect for cartilage erosions of the femoral trochlear sulcus. Fig. 8 shows full thickness cartilage erosion (circled light blue) of the proximal medial trochlear ridge where the patella has been luxating, a relatively shallow trochlea and a medial trochlear ridge with poor height.



12.

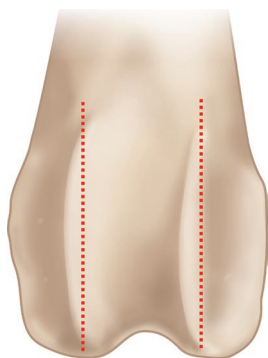
Remove the Gelpi retractors, retroflex the patella and assess the articular cartilage damage on the caudal aspect of the patella. Fig. 9 shows a large full thickness articular cartilage defect on the caudal aspect of this patella (circled light blue); this may adversely affect prognosis.



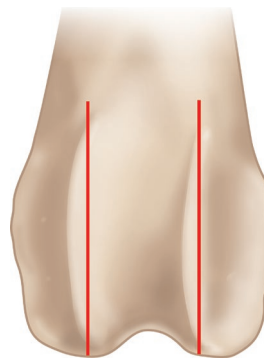
## Block Recession Sulcoplasty

Assess the depth of the femoral trochlear sulcus and the need for sulcoplasty; this is a subjective judgement. If the trochlear sulcus is deep enough, sulcoplasty is not necessary. When assessing whether to perform sulcoplasty or not, consider that the detrimental effect of sulcoplasty is unavoidable cartilage damage. This needs to be carefully balanced against the benefits.


In adult dogs, block recession sulcoplasty is the best option as it preserves the largest amount of articular cartilage, it enables a larger amount of the sulcus to be deepened, and it creates a deeper femoral trochlea proximally compared to wedge recession sulcoplasty. However, it is also the most fiddly and technically demanding method and requires precise surgical technique. It is challenging to do this procedure well single-handed; a surgical assistant is necessary.



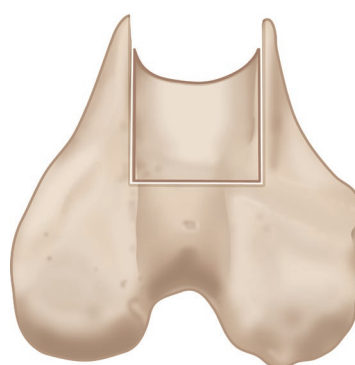
1. Scalpel blade used to gently score the boundaries of the sulcoplasty.



2. Lateral and medial saw cuts made to define the edges of the osteochondral block.



3. Osteochondral block removed using a modular osteotome.



4. Further bone removed, from either the base of the block or from the exposed femur. The block is then replaced in its new recessed position.



1.

Determine the width of the intended sulcoplasty by choosing an osteotome blade that best fits the maximum width of the trochlea. Using a #11 blade, gently score the intended cut position on the medial and lateral trochlear ridges.

2.

Using a fine-toothed hand saw, make the lateral and medial cuts that will define the edges of the osteochondral block. (Fig. 10). Make sure the base of the cuts are flat and not domed. Be careful to make the osteotomy as wide as possible, yet leave enough lateral and trochlear ridge width that neither is weakened.

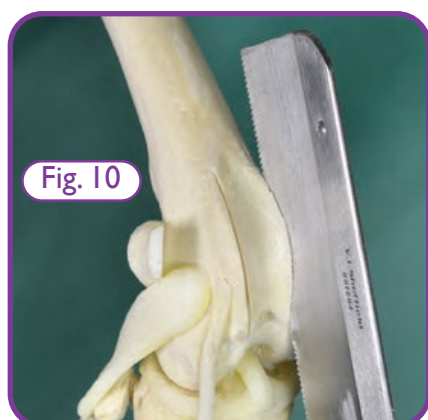

Fig. 10

3.

Use a modular osteotome and mallet to cut the base of the block from distal to proximal (Fig. 11). Start just cranial to the intercondylar notch and aim for the osteochondral junction of the trochlear groove proximally. This must be done very carefully to avoid fracturing the block. If the block fractures, it can be salvaged, but this may be difficult to achieve. A thick osteotome blade will increase the chance of fracture, so a thin osteotome blade is much preferred.

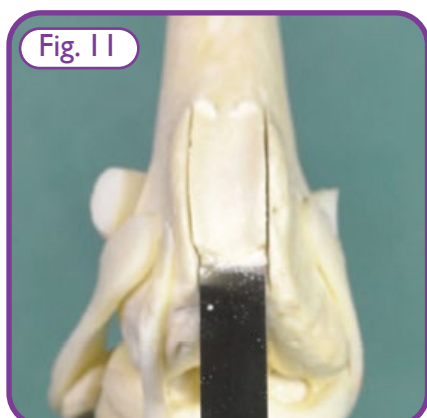


Fig. 11

4.

Carefully remove the osteochondral block from the femoral trochlea (Fig. 12).

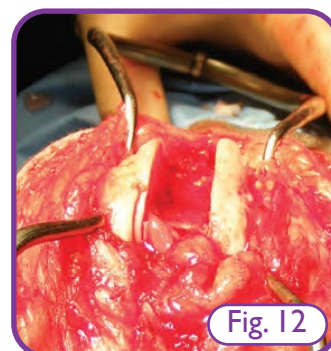


Fig. 12

5.

Recess the block by taking further subchondral bone away, either from the exposed femoral subchondral bone or from the base of the osteochondral block. Further subchondral bone is best removed either using the modular osteotome, or a bone/trochlear rasp. It is important to achieve a smooth, flat surface so the use of rongeurs is not advisable.

6.

Re-position the osteochondral block in the graft site and review for closeness of fit, stability, and depth of recession achieved (Fig. 13). Adjust until satisfactory and stable.

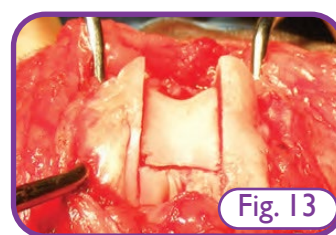


Fig. 13

7.

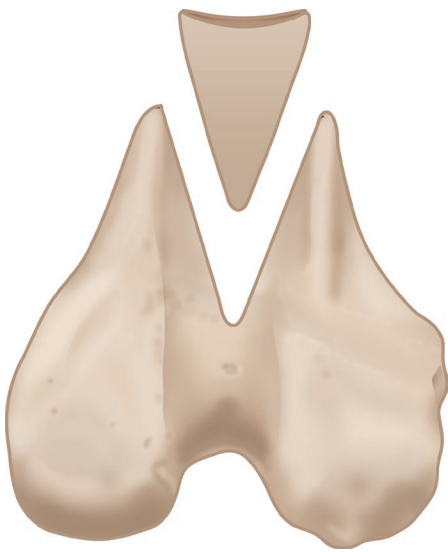
Remove the Gelpi retractors, return the patella to the trochlear sulcus and assess the patella for normal tracking and medial-lateral stability.

Patellar luxation should be resolved prior to soft tissue closure - do not rely on soft tissue closure to ensure patellar stability.

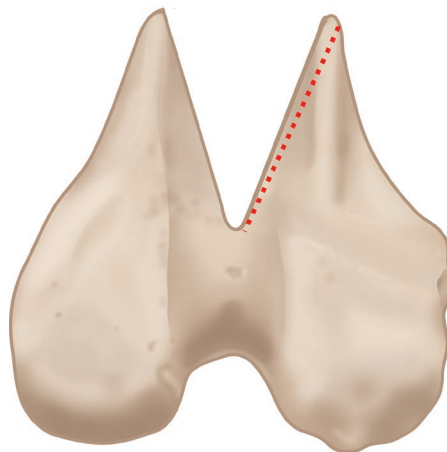
## Wedge Recession Sulcoplasty

Assess the depth of the femoral trochlear sulcus and the need for sulcoplasty; this is a subjective judgement. If the trochlear sulcus is deep enough, sulcoplasty is not necessary. When assessing whether to perform sulcoplasty or not, consider that the detrimental effect of sulcoplasty is unavoidable cartilage damage. This needs to be carefully balanced against the benefits.

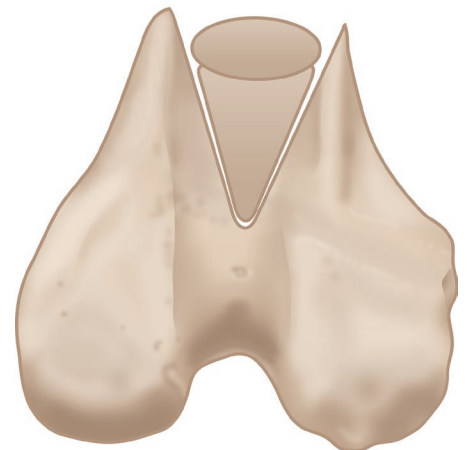Wedge recession sulcoplasty is the next best option to a block recession sulcoplasty as it preserves some articular cartilage, but it does not deepen the trochlear sulcus as effectively as performing a block recession. It is, however, simpler to perform, can be done with less specialised equipment or experience, and the risk of graft fracture is less.



*1. Blade used to score the highest points of the trochlear ridges. Saw cuts made to create an osteochondral wedge.*



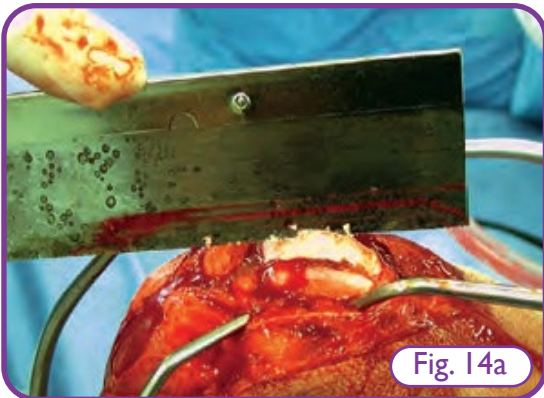
*2. Thin section of subchondral bone is removed from the exposed femoral trochlear sulcus.*



*3. Wedge replaced into recessed femoral sulcus. Patella replaced and assessed.*

1.

Using a #11 blade, score the highest points of the medial and lateral trochlear ridges of the femur; this marks the cutting points. Using a fine-toothed hand saw, create an osteochondral wedge from the trochlear sulcus. The lateral and medial saw cuts should be oriented to meet just cranial to the intercondylar notch of the femur distally and proximally at the osteochondral junction (Figs. 14a and 14b).



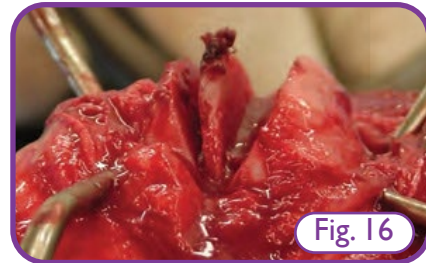2.

Carefully remove the cut wedge from the femoral trochlea (Figs. 15a and 15b).



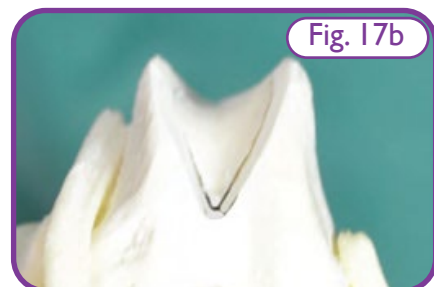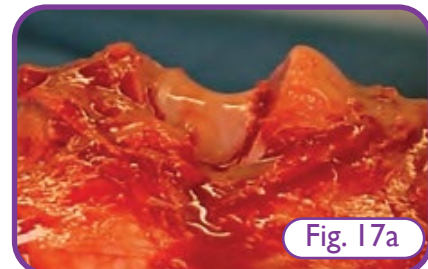3.

Recess the wedge by removing a further thin section of subchondral bone; either from the exposed femoral trochlear sulcus (Fig. 16) which is best, or from the wedge itself but the latter is much more difficult and will make the wedge narrower and lose more articular cartilage.



4.

Replace the osteochondral wedge in the recessed femoral sulcus and review for closeness of fit, stability, and depth of trochlear recession achieved. Adjust until satisfactory (Figs. 17a and 17b). Some surgeons prefer to remove subchondral bone from the base (apex) of the wedge with rongeurs; this can give a better fit and stop the graft from rocking on the ridge of the base.



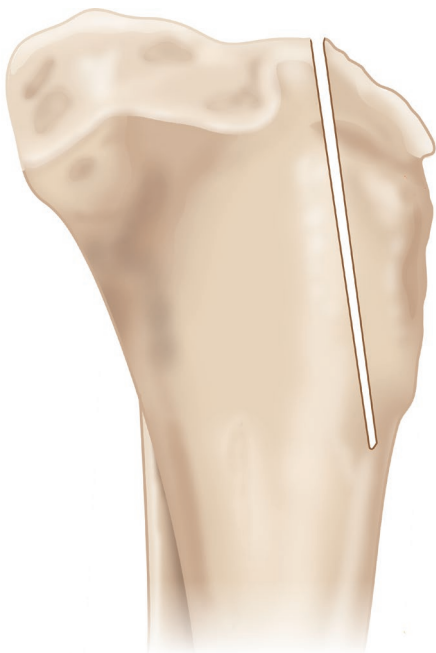5.

Remove the Gelpi retractors, return the patella to the trochlear sulcus and assess the patella for stability through a full range of physiological stifle movement, specifically flexing from full extension with tibial internal rotation - these are the positions most likely to cause luxation.

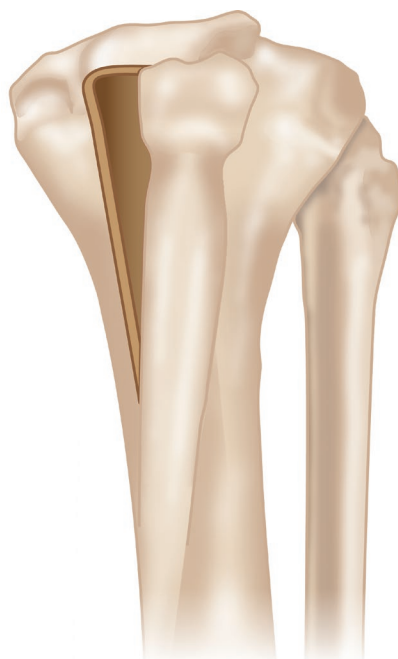Patellar luxation should be resolved prior to soft tissue closure - do not rely on soft tissue closure to ensure patellar stability.

## Tibial Tuberosity Transposition

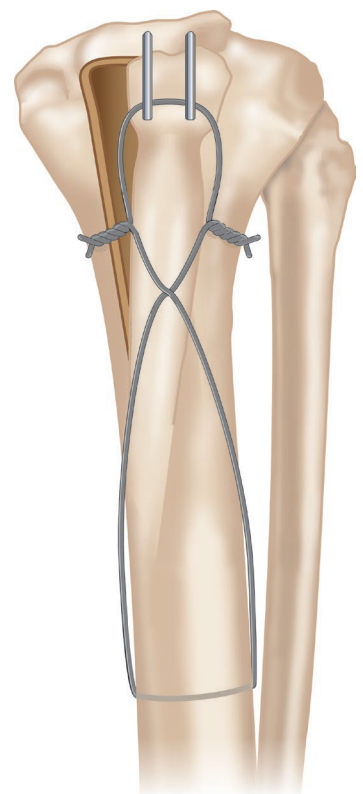
Assess the need for tibial tuberosity transposition prior to surgery. An indication should have been derived from physical examination and radiographs or CT scan. The dog should be in dorsal recumbency. Stand at the foot of the dog, looking up the pelvic limb. Hold the stifle in full extension. Observe the orientation and position of the patellar ligament, patella and tibial tuberosity whilst the stifle is extended and flexed and the tibia is rotated internally and externally; the most likely position for patellar luxation is flexing with internal tibial rotation. If patellar ligament orientation is not neutral and patellar luxation occurs, tibial tuberosity transposition is indicated.



1. An osteotomy of the tibial tuberosity is performed according to pre-operative planning.



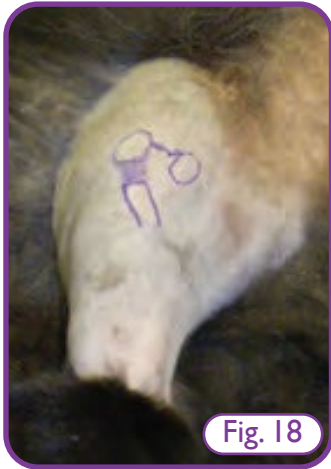2. The tibial tuberosity is transposed laterally to a position that achieves neutral orientation of the patellar ligament and quadriceps mechanism.



3. The transposed tibial tuberosity is secured in position using parallel K-wires and a figure-of-8 tension band wire.

1.

Identify the relative positions of the patella (reduced and luxated), the position of the tibial tuberosity and the medial orientation of the patella, patellar ligament and tibial tuberosity (Fig. 18).



2.

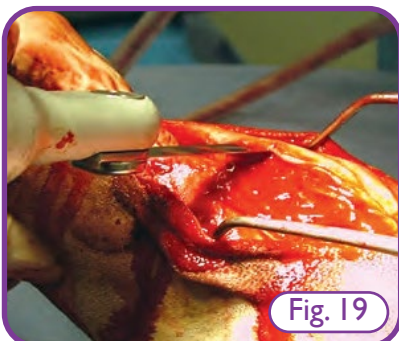
Use sharp dissection (#11 blade and periosteal elevator) to expose the medial aspect of the tibial tuberosity.

3.

If using a finger saw or hacksaw (not if using an oscillating saw), sharply dissect and elevate the cranial tibial muscle from the lateral tibial tuberosity. Ensure that the most proximal attachments of the muscle are not severed i.e. the muscle should only be partially elevated to minimise damage from the saw blade, but not fully elevated.

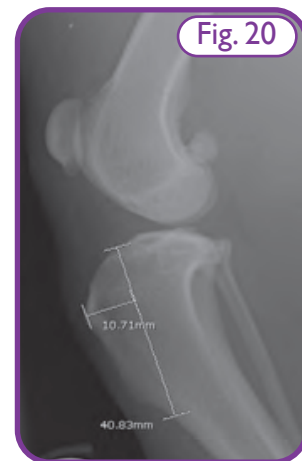4.

Perform an osteotomy of the tibial tuberosity (Fig. 19). An oscillating saw gives the most controlled and precise cut but alternatively use a hand saw, bone cutters or osteotome. Place a Freer elevator or Gelpi retractor under the patellar ligament to protect it from the saw.



4.

The size of tibial tuberosity and position of osteotomy is important to minimise the chance of fracture. As a guide, the craniocaudal depth of the osteotomised tibial tuberosity should be about 30% the craniocaudal dimensions of the tibia at that point. The osteotomy should go between the proximal tibia and the base of the tibial tuberosity, keeping a bridge of intact cortical bone and periosteum distally. Fig. 20 shows a good pre-operative plan for size and position of the tuberosity osteotomy; a sterile ruler can be used during surgery to replicate the measurements and ensure the osteotomy is in the correct position. If the osteotomy is made in the wrong position, either the tibial tuberosity or the tibia are at risk of fracture.



5.

The tibial tuberosity should now be mobile proximally (medial to lateral) but the distal aspect should remain attached. Using a periosteal elevator, gently and minimally elevate the tibial tuberosity from the tibia and transpose it laterally to a position that achieves neutral orientation of the patellar ligament and quadriceps mechanism (Fig. 21). If the tuberosity is not readily mobile, this usually means the osteotomy is not sufficiently complete and needs slightly more work distally. Some surgeons like to prepare the graft bed prior to tibial tuberosity fixation; to do this, the ridge from the lateral edge of the parent tibial tuberosity site is removed using rongeurs.

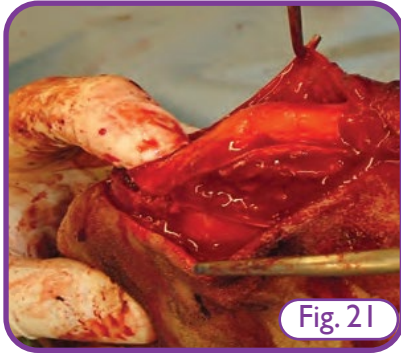


Fig. 21

6.

Using a power drive where available, place a K-wire into the proximal tibial tuberosity just proximal to the distal insertion point of the patellar ligament. This immobilises the tibial tuberosity in its new laterally transposed position (Fig. 22, 23 and 24).

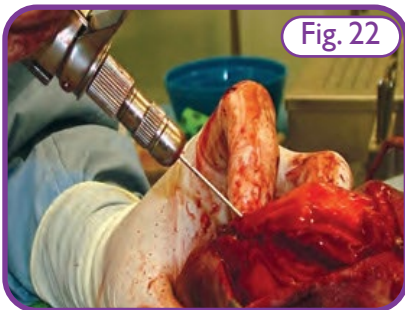


Fig. 22



Fig. 23

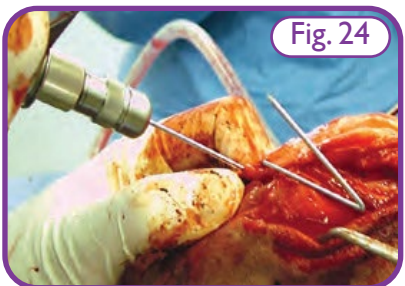


Fig. 24

The K-wire should be directed slightly cranio-lateral to caudo-medial. Ideally two parallel K-wires are placed adjacent to each other. The size of K-wire should be appropriate to the patient. A hand-driven Jacobs chuck can be used to drive the K-wires if a power tool is not available, but slippage and bending of the wires may occur. A powered wire driver makes placement of the K-wires much easier and more accurate.

7.

Application of a figure-of-8 tension band (Figs. 25a and 25b) is highly advisable; care must be taken during placement to avoid damaging the soft tissues, particularly the patellar ligament.

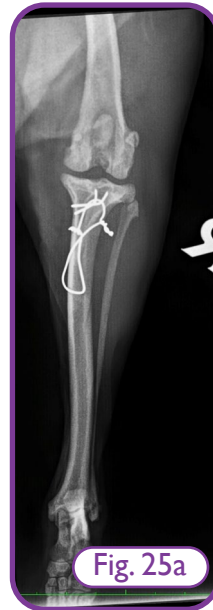

Fig. 25a

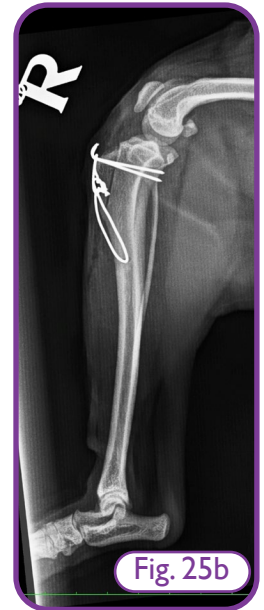

Fig. 25b

8.

Looking from the position of the dog's foot, review the orientation of the patellar ligament and the position of the tibial tuberosity. The patellar tendon/ ligament should be in a neutral position. Internal and external rotation of the tibia should cause equal medial and lateral orientation of the patellar ligament with no patellar luxation with internal and external rotation respectively; note the changing alignment of the patellar ligament as the tibia is rotated.

9.

Review the stability of the patella and specifically assess for luxation. Start with the stifle in full extension and slowly flex with the tibia in full internal and then external rotation as these are the positions most likely to cause (medial and lateral) luxation. The patella should now be stable through a full range of normal physiological movement and should not luxate.

Patellar luxation should be resolved prior to soft tissue closure - do not rely on soft tissue closure to ensure patellar stability.

## Other Potential Surgical Techniques

### Medial Release

Medial release is not necessary for most cases. It is however necessary when the tension in the medial tissues is such that the patella cannot be returned to the trochlear sulcus without performing release, or if the tension is adversely influencing patellar tracking i.e. grade 4 or severe grade 3 patellar luxation. If medial release is to be performed, it is best performed as the first step i.e. before femoral trochlear sulcoplasty, and certainly before tibial tuberosity transposition. To perform medial release, a medial approach is made to the stifle in a similar way as described above for the initial surgical approach. The incision extends far enough proximally until all excessive soft tissue tension has been abolished. In most dogs, this means releasing both the medial retinaculum and the joint capsule in the region of and just proximal to the stifle. If severe, the release may need to extend up to the proximal femur and pelvis.

### Lateral Imbrication

For most cases of patellar luxation, once sulcoplasty and tibial tuberosity transposition have been performed, the patella should be stable, luxation should not be possible and further surgery (other than routine closure) should not be necessary. If the patella is not stable at this stage, the trochlear sulcoplasty and tibial tuberosity transposition should be critically reviewed, and revised as necessary. Performing lateral imbrication without adequate trochlear sulcoplasty or tibial tuberosity transposition is not recommended as it is associated with a high risk of patellar re-luxation.

Lateral imbrication tightens the soft tissues on the lateral aspect of the stifle joint; the joint capsule and retinaculum can be closed separately. Imbrication can be achieved by one of two methods:

1) Using Mayo scissors, resect a strip of tissue from one edge of the retinaculum and/or joint capsule. Do not take so much tissue that it cannot then be sutured together. The tissue should close snugly but without tension. Close the joint capsule and retinaculum separately

with simple interrupted appositional sutures.

2) Place modified Mayo Mattress (vest over pants) sutures to close the retinaculum and/or joint capsule in an overlying instead of an appositional fashion.

### Abrasion Sulcoplasty (Rasping)

A conical bone rasp is used to rasp the trochlear sulcus until adequate depth is achieved. This is the least favourable option as all articular cartilage is destroyed. This technique is not recommended unless no articular cartilage is present, which is unlikely except in revision surgery. Inexperienced surgeons may choose to start using this technique, particularly in very small stifles where the osteotomy techniques described above may be challenging and carry a risk of fracture of the osteochondral graft or the femur if the cuts are made too deep.

### Chondroplasty

The articular cartilage of the trochlear sulcus is sharply dissected away from the subchondral bone and remains attached distally. The underlying bone is deepened, then the articular cartilage is laid back in the trochlear groove. This is rarely performed as it can only be done in very young patients (less than 6 months) of age as the cartilage is not flexible enough in older patients.



## Closure

Before considering the surgery complete, once again check patellar stability through a normal physiological range of stifle movement, particularly flexing the stifle from full extension with tibial internal and external rotation. If patellar luxation persists, the surgery needs to be reviewed and revised. The surgical site should be flushed thoroughly and then closed:

- Appose and close the joint capsule incision (unless release was performed, then not on that side).
- Appose and close the retinacular incision (unless release was performed, then not on that side).
- Appose and close the subcutaneous fascia.
- Appose and close the skin.

Post-operative radiographs of the stifle are taken to confirm the patella has been returned to the trochlear sulcus, that the positions of the sulcoplasty and tibial tuberosity transposition are correct and appropriate, and that implants are in the correct position. Radiographs should be critically assessed for potential problems before the patient is recovered from the anaesthetic.

With thanks to Gareth Arthurs PGCertMedEd MA VetMB CertVR CertSAS DSAS(Orth) FHEA FRCVS RCVS Recognised Specialist in Small Animal Surgery (Orthopaedics) for his invaluable assistance with the revised version (2023) of this Surgery Guide.

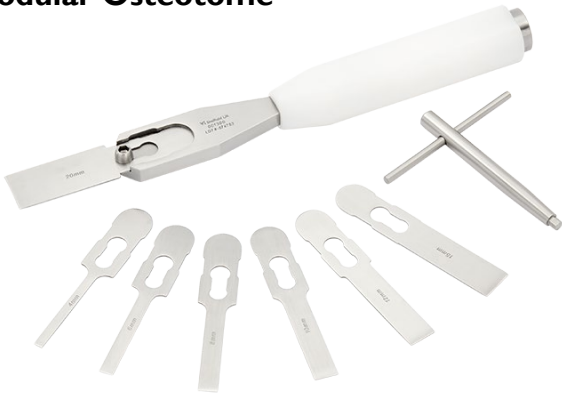



## Featured Products

Please note, the following featured products are only a selection of those available in the range.

### Modular Osteotome



- 001382 Modular Osteotome Replacement Blade 4mm
- 001390 Modular Osteotome Replacement Blade 5mm
- 001383 Modular Osteotome Replacement Blade 6mm
- 001384 Modular Osteotome Replacement Blade 8mm
- 001385 Modular Osteotome Replacement Blade 10mm
- 001386 Modular Osteotome Replacement Blade 12mm
- 001387 Modular Osteotome Replacement Blade 15mm
- 001388 Modular Osteotome Replacement Blade 20mm
- 001389 Modular Diamond Rasp 6mm
- 001380SCREW Spare Screw For Modular Osteotome
- 001380 Modular Osteotome With 7 Blades
- TBHEX40 4.0mm T Bar Hex Driver

### Gordon Coronoid Osteotome



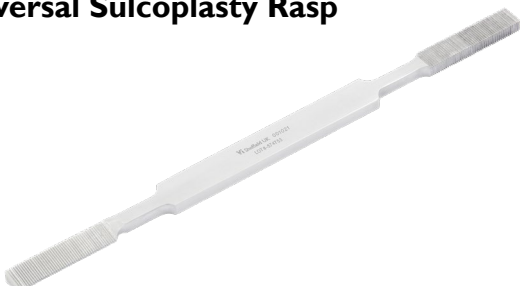- AR-17-30 Gordon Coronoid Osteotome (4mm)
- AR-17-29 Gordon Coronoid Osteotome (2mm)

### Rectangular Sulcoplasty Instruments



- 001017 Super Slim Osteotome 8mm 180mm
- 001018 Rectangular Bone Rasp 210mm

### Universal Sulcoplasty Rasp



- 001021 Universal Sulcoplasty Rasp 210mm Long

### Osteophyte Rasp



- 001019 Osteophyte Rasp

### Trochlea Rasp



- 001020 Trochlea Rasp 11mm max 5mm Min Diameter
- 001022 Trochlea Rasp Small 8mm max 3mm Min Diameter

### Extra Fine Hard Back Saw



- 73547 Extra Fine Hard Back Saw Depth 31mm

### Orthopaedic Hard Back Saw



- 001004 Orthopaedic Hard Back Saw

### Adjustable Bone Saw



- 001000 Adjustable Bone Saw c/w 5 Fine Blades
- 001001-A Spare Fine Blades Pack of 5 Chrome Plated

## Vi Black Series Battery Powered Drill/Saw Set



- BLACKKITUK** Vi Black Series Drill & Saw Set UK  
**BLACKKITEU** Vi Black Series Drill & Saw Set EU  
**BLACKKITUS** Vi Black Series Drill & Saw Set US

Please contact a member of the Vi team for a list of the contents of this kit.

## Multi Saw Battery Powered System




- 001708** Multi Saw Surgical Kit incl Converter, Shroud, Titanium Nitride Coated Blade & S82-103 Blade  
**001708.134** Multi Saw Surgical Kit incl Converter, Shroud, Titanium Nitride Coated Blade & SB5071-134 Blade Suitable for TTO & TTA Rapid  
**001702** Stainless Converter (c/w Spanner)  
**001703** Waterproof Shroud For Multi Saw  
**001705** Multi Saw Diamond Blade  
**001714** Multi Saw Titanium Nitride Coated Blade  
**MI2B2MIL** Spare Battery For Multi Saw (Milwaukee)  
**MI218FCMIL** Battery Charger/Replacement - Milwaukee

## Variable Speed Orthopaedic Drill (Milwaukee) & Accessories



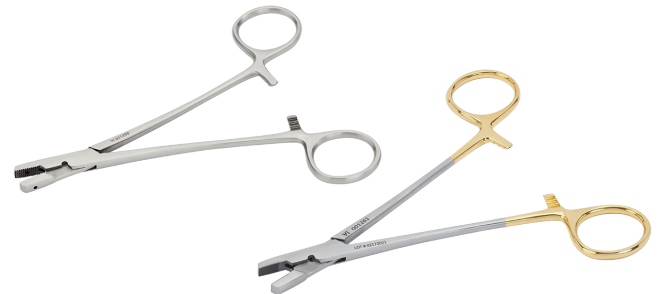- 001600** Variable Speed Orthopaedic Drill (Milwaukee) Kit - Drill, Chuck, Key, Shroud, Extension & 2x Batteries  
**001605** Spare Chuck (& Key) 1/4" 6.35mm  
**001606** Spare Key For Standard Chuck  
**001607** Drill Extension  
**001661A** Waterproof Shroud  
**MI2B2MIL** Spare Rechargeable Battery - Milwaukee Drill  
**MI218FCMIL** Battery Charger/Replacement - Milwaukee Drill  
**001620** Waterproof Drill Shroud for Pre-2014 Makta Style Drill

## Orthopaedic Wire



- OW0210** 32g Reel of Orthopaedic Wire 0.20mm  
**OW0310** 30g Reel of Orthopaedic Wire 0.30mm  
**OW0410** 27g Reel of Orthopaedic Wire 0.40mm  
**OW0510** 25g Reel of Orthopaedic Wire 0.5mm  
**OW0610** 24g Reel of Orthopaedic Wire 0.6mm  
**OW0710** 22g Reel of Orthopaedic Wire 0.71mm  
**OW0810** 21g Reel of Orthopaedic Wire 0.8mm  
**OW0910** 20.5g Reel of Orthopaedic Wire 0.9mm  
**OW1010** 20g Reel of Orthopaedic Wire 1.0mm  
**OW1012** 18g Reel of Orthopaedic Wire 1.2mm  
**OW1015** 16g Reel of Orthopaedic Wire 1.5mm

## Wire Twister/Shear Cutter



- 001260** Wire Twister/Shear Cutter 165mm Long  
**001261** Wire Twister/Shear Cutter - Tungsten Carbide Jaws 165mm Long

## Kirschner Wire 125mm Long

- 090030KIR** 0.9mm Kirschner Wire 125mm Pack of 10  
**090070KIR** 1mm Kirschner Wire 125mm Pack of 10  
**090031KIR** 1.1mm Kirschner Wire 125mm Pack of 10  
**090071KIR** 1.25mm Kirschner Wire 125mm Pack of 10  
**090034KIR** 1.4mm Kirschner Wire 125mm Pack of 10  
**090072KIR** 1.5mm Kirschner Wire 125mm Pack of 10  
**090032KIR** 1.6mm Kirschner Wire 125mm Pack of 10  
**090073KIR** 1.8mm Kirschner Wire 125mm Pack of 10  
**090033KIR** 2.0mm Kirschner Wire 125mm Pack of 10  
**090030MIX** Pack of Mixed Kirschner Wires

## Arthrodesis Wire 125mm Long

- 090054ART** 0.8mm Arthrodesis Wire 125mm Pack of 10  
**090020ART** 0.9mm Arthrodesis Wire 125mm Pack of 10  
**090060ART** 1.0mm Arthrodesis Wire 125mm Pack of 10  
**090021ART** 1.1mm Arthrodesis Wire 125mm Pack of 10  
**090061ART** 1.25mm Arthrodesis Wire 125mm Pack of 10  
**090024ART** 1.4mm Arthrodesis Wire 125mm Pack of 10  
**090062ART** 1.5mm Arthrodesis Wire 125mm Pack of 10  
**090022ART** 1.6mm Arthrodesis Wire 125mm Pack of 10  
**090026ART** 1.8mm Arthrodesis Wire 125mm Pack of 10  
**090023ART** 2.0mm Arthrodesis Wire 125mm Pack of 10  
**090025ART** Pack of Mixed Arthrodesis Wires

## Jacobs Chuck



001220 Small Jacobs Chuck with Handle 5/32" Capacity 260mm

001221 Standard Jacobs Chuck with Handle 1/4" Capacity

## Small Pin Vice



001223 Small Pin Vice 100mm Long

## 'K'/'A' Wire/Small Pin Punch



001360 'K'/'A' Wire & Small Pin Punch 135mm Long

001361 'K'/'A' Wire & Very Small Pin Punch 1.6mm Tip 135mm Long

## 'K' Wire Bender



001362 'K' Wire/Small Pin Bender 140mm Long

## Implant Cutters

Please refer to the Vi catalogue or website to view the full range of Implant Cutters as there are multiple options available.



Exclusively distributed by



A **covetrus**  Company

**Visit Provet Vi Online**

[www.vetinst.com.au](http://www.vetinst.com.au)

[www.vetinst.co.nz](http://www.vetinst.co.nz)

